

Case Report

Open Access, Volume 1

Isolated Adrenal Metastasis of Breast Invasive Ductal Carcinoma: Case Report of an Uncommon Finding and Review of Literature

*Patricia Ciriano Hernández**; *Paloma Núñez Guerrero*; *Bruno Juan Menchén Trujillo*; *Cristina Vera Mansilla*; *Enrique Calcerrada Alises*; *Jesús Martín Fernández*

Department of General and Digestive System Surgery, General University Hospital of Ciudad Real, Spain.

Abstract

Background: Adrenal glands are a common site for metastasis. It is uncommon for Breast Invasive Ductal Carcinoma (BIDC) to spread to the adrenal glands. There are few cases describing this clinical entity in recent literature, and as a result, there is a lack of information about management and outcome of the patients affected.

Case presentation: We present the case of a patient diagnosed of an adrenal metastasis. She had a previous history of a radical modified mastectomy and lymphadenectomy followed by chemotherapy, hormonal treatment and radiation, due to a BIDC eleven years before. She went under total laparoscopic adrenalectomy and radiation, and is alive and free of disease at the time of writing.

Discussion: Adrenal masses are a common finding in general practice and are of great importance in cases of a previous oncological history. It is mandatory to assess the origin of the mass, determine its radiological features, discharge functionality, and even search for a primary tumor. Adrenal solitary metastasis of breast invasive carcinoma is a rare finding. If we focus on BIDC, this diagnosis is even more infrequent. Adrenal metastasis of other malignancies, have been successfully treated performing a total adrenalectomy. In addition, the few previous cases described, suggest that this treatment could be a feasible option in case of BIDC adrenal metastasis.

Conclusions: Adrenal metastasis of BIDC is an infrequent diagnosis on clinical practice. In some cases, total adrenalectomy might be a feasible option if patients are carefully selected and primary tumor is under control. This might improve patient's outcome and disease-free survival. It is important to draw conclusions carefully and individualize management and indications of surgery due to the lack of information and the need for more clinical trials and investigation.

Keywords: Adrenal metastasis; breast carcinoma; case report; literature review

Manuscript Information: Received: April 22, 2020; Accepted: May 25, 2020; Published: May 27, 2020

Correspondance: *Patricia Ciriano Hernández*, Department of General and Digestive System Surgery, General University Hospital of Ciudad Real, Ciudad Real, Spain, 13005. email: patricia.ciriano.hernandez@gmail.com

Citation: *Ciriano Hernández P, Núñez Guerrero P, Menchén Trujillo BJ, Vera Mansilla C, Calcerrada Alises E, Martín Fernández J, et al. Isolated Adrenal Metastasis of Breast Invasive Ductal Carcinoma: Case Report of an Uncommon Finding and Review of Literature. J Surgery. 2020; 1(3): 1012.*

Copyright: ©Ciriano Hernández P 2020. Content published in the journal follows creative common attribution license

Background

Adrenal glands are a common site for metastasis of a wide variety of tumors, being the most frequent lung, gastrointestinal tract and renal. Those clinical entities have to be considered in the differential diagnosis of adrenal masses, especially in case of a previous oncologic history [1-4]. Invasive breast carcinoma tends to metastasize to different organs and rarely to the adrenal gland. The most frequent sites for metastasis of Breast Invasive Lobular Carcinoma (BILC) are gastrointestinal system, gynecologic organs, peritoneum, retro peritoneum, bone- marrow and adrenal glands. On the contrary, Breast Invasive Ductal Carcinoma (BIDC), metastasizes to lung and pleura, and it is extremely rare to find an adrenal gland metastasis [5]. Only a few cases of BIDC adrenal metastasis have been described [6-10]. This is a rare clinical entity, and as a consequence the treatment is still unclear, although adrenalectomy is widely accepted in cases of solitary adrenal metastasis from other primary malignancies, as it may improve life expectancy and patient prognosis [1-3]. Due to the lack of information about this infrequent topic, our main objective is to report a real clinical case recently diagnosed and treated in our hospital. This might help other clinicians to face adrenal metastasis of BIDC or develop studies to clarify its treatment and outcome.

Methods

In December 2018, a 64-year-old woman was admitted to our hospital for surgical treatment after diagnosis of a right adrenal metastasis. The patient, who was asymptomatic, had a previous history of BIDC eleven years before. In 2007 she was diagnosed of a right 4 cm BIDC with skin involvement (cT4cN2a). She received neoadjuvant chemotherapy based on docetaxel, epirubicin and c0, according to the TNM classification after neoadjuvant chemotherapy.

After breast surgery the patient completed adjuvant treatment following the same chemotherapy pattern and hormone therapy (letrozol). She went under radiation treatment also, receiving a total of 50 Gy over surgical site. The patient continued follow up in our hospital during the next ten years without any evidence of local or distant recurrence, until September 2018, when the right adrenal metastasis showed up. The adrenal mass was discovered after a CT scan during the follow up of a previously treated BIDC. CT scan showed an image of a 10 × 5.5 cm right adrenal mass (Figures 1 & 2). This finding was confirmed in MRI (Figure 3). The mass presented an irregular shape, necrotic and heterogeneous aspect, highly suggestive of a malignant lesion related to the patient's oncological history. In addition to these findings, laboratory test showed progressive elevation of Ca 15- 3.

After confirmation of negative laboratory function test, a CT scan guided biopsy was performed to confirm its metastatic nature prior to surgical treatment. On December 2018, the patient underwent a right laparoscopic adrenalectomy and after a non-complicated postoperative course, she was discharged five days later.

Histological examination confirmed a BIDC metastasis. Inmuno-histochemical analysis was 95% positive for estradiol receptors and 60% positive for progesterone receptors, Ki67 expres-

sion of 20 % and was weakly positive for HER -2 receptor (+/+++). Because of the positive conversion of HER -2 a new inmuno-histochemical analysis was performed, and finally HER-2 receptor was found to be negative. As tumor was adjacent to specimen margin, after surgery, the patient underwent radiation treatment. After confirmation of negative HER-2 receptor, hormone treatment based on letrozol was settled, in combination with palbociclib. Fourteen months after surgical treatment the patient is still alive and free of disease, as it has been confirmed by a routine CT scan part of her oncologic follow up.

Discussion

Adrenal incidentaloma is a common finding nowadays due to the widespread use and the improvement of different image techniques [1]. The most frequent masses are adenomas, while metastasis is the second, accounting for a 2, 5 % of the diagnosed adrenal masses. That explains why, once functional diagnosis is completed, and primary malignancy of the adrenal gland is rejected, sometimes it could be necessary to search for a primary tumor, even if there is no previous oncologic history [1-3]. Metastasis must be suspected if there is oncologic history and an adrenal mass exceeding 2 cm, especially if it presents some radiological features such as irregular shape, necrotic areas, loco-regional invasion, rapid contrast washout or high metabolic activity [1,2]. Other authors support a positive predictive value of the measure of precontrast Hounsfield Unit (HU) of the adrenal mass. According to their observations a cut- off point for adrenal metastasis is a precontrast HU exceeding 36, 2 [4]. Function test must be performed, as upto 50 % of adrenal masses are benign even in the presence of a primary tumor [2]. It is important to confirm the metastatic status. This requires to rule out the possibility of a functional mass, prior to perform a CT scan guided biopsy or a fine needle aspiration. It is also crucial to search for widespread disease, as this finding will be a determinant factor in the treatment choice [1,2]. Adrenal metastasis can be diagnosed at the same time than the primary tumor or during follow-up, though are more often metachronous. They can be bilateral and sometimes translate disseminated disease [1-4]. Patients are typically asymptomatic, but they can also present non- specific symptoms due to hormonal insufficiency or an Addisonian crisis. Other symptoms are abdominal or back pain and retro-peritoneal hemorrhage. In case of a symptomatic patient it is more frequent to find bilateral or diffuse invasion of the adrenal gland, and also widespread disease [1,2].

The most frequent origin of adrenal metastasis is lung, gastrointestinal tract, renal and breast cancer, as well as hepatocarcinoma and melanoma [1,2]. Some other studies suggest that the frequency of the primary tumor varies depending of the geographical location and the rate of the assessed tumors in a specific population (Table 1). As an example, Lam et al. found a high prevalence of adrenal liver and bile duct metastasis, due to its high incidence in Hong Kong [3]. About the diagnosis of adrenal metastasis of breast cancer, data research shows a wide range of incidence: between 2, 5 % and 35 %, according to different series [1,4]. If a more accurate analysis is performed, to determine the incidence of adrenal metastasis of BILC versus BIDC, the conclusion is that adrenal metastasis from BIDC are a very rare finding [5]. Bort et al. reviewed a series of 2605 breast carcinoma during

a period of 18 years. In spite of a majority of BIBC (86, 2 % versus 13, 8 % BILC) they found no cases of adrenal metastasis. Two cases of adrenal metastasis of BILC were found, which accounted for a 0, 6 % of the total of this subtype site of metastasis [5]. There are only a few cases of adrenal metastasis from BIBC in literature. The first case was reported by Liu et al. and was published in 2010 [6]. Since then, a few more cases have been identified [7-10]. Most cases are diagnosed as an asymptomatic adrenal incidentaloma during follow up after treatment of the primary tumor, consisting on radical modified mastectomy [6-10]. After surgery, or prior to it, if important tumor size, those patients required chemotherapy treatment [6-10]. In two cases also needed radiation and hormone therapy [9,10]. In two cases the hormone status of both the primary breast carcinoma and the adrenal metastasis was assessed. One case showed negative estrogen and progesterone receptor and kept negative determinations in the metastasis, while other case showed negative receptors in the primary tumor and turned positive in the adrenal gland. HER-2 remained positive in both specimens in the two cases [6,7]. Two patients remained free of disease at least three years after adrenalectomy [6,8], and other two at the time of writing months later [9,10]. In one case, the patient suffered a tumor relapse involving the remaining adrenal gland, retro-peritoneal lymph nodes and lately multiple brain metastasis [7]. In this article we present a recently diagnosed and treated case to add more information to previous literature. According to literature, the adrenal metastasis was diagnosed in an asymptomatic patient, who had gone under mastectomy eleven years before. Image, function tests and CT scan guided biopsy confirmed the metastatic origin from breast carcinoma. One year after laparoscopic adrenalectomy, followed by radiation, hormone treatment and chemotherapy the patient is free of disease, still under clinical surveillance. The management of adrenal metastasis once diagnosed depends on various factors, being the most important objective to avoid unnecessary harm to the patient, in case of disseminated disease [1]. Surgical treatment of solitary adrenal metastasis has become an accepted treatment. It is mandatory to confirm the extra-adrenal control of the primary tumor prior to perform an adrenalectomy. Candidates for surgical resection are those patients presenting with solitary involvement of the adrenal gland, or concomitant resectable metastasis [1]. Some researchers have found out that adrenalectomy may influence in patient prognosis, increasing the 5-year survival rate to 20- 45% [1]. This resection may increase survival in cases of isolated adrenal metastasis, if control of the primary tumor has been previously achieved, which is especially patent in cases of disease-free interval longer than 6 months [1,2]. The most important factors to prevent recurrence are the complete resection of the adrenal gland, which includes free tumor margins [1-3]. About the approach (laparoscopic versus conventional surgery) many authors supported the conventional technique to achieve a complete resection avoiding tumor fracture, which would lead to a malignant cell dissemination along the abdominal cavity. Nowadays laparoscopy is widespread and feasible, and has become the treatment choice for many benign adrenal masses. In addition, most surgeons are familiar to these techniques. It is even preferred, due to a minor blood loss and faster patient recovery. The key point is to guarantee that laparoscopic adrenalectomy is equivalent to conventional surgery in oncologic terms of adequate resection margins, recurrence and survival. This would lead to a proper selection of patients [1,2].

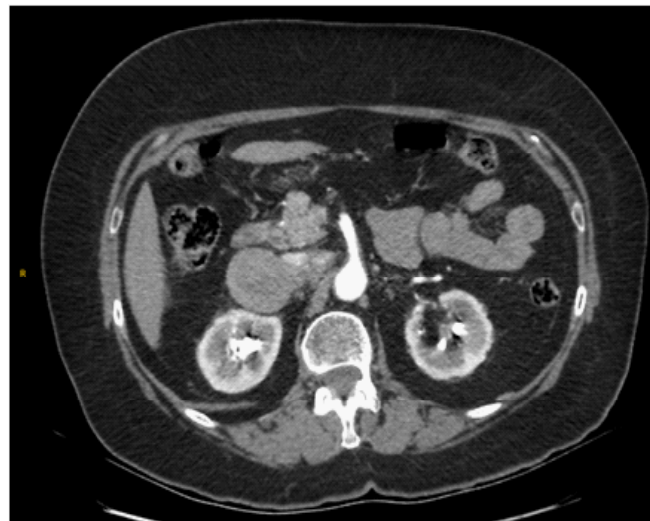

Figure 1: CT scan showing BIBC metastases to right adrenal gland.

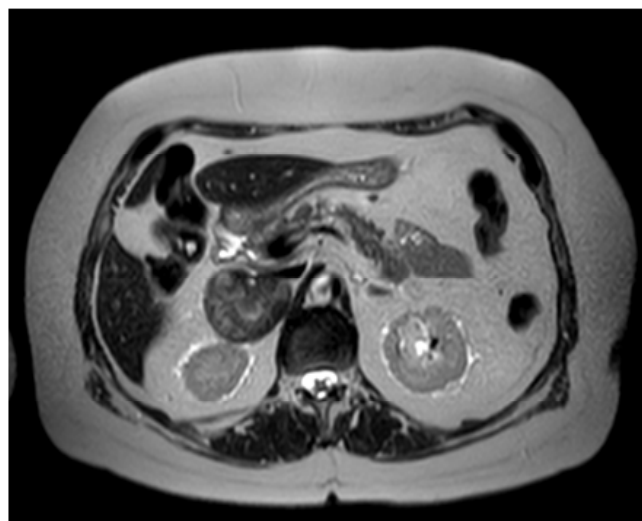

Figure 2: MRI showing BIBC metastases to right adrenal gland.

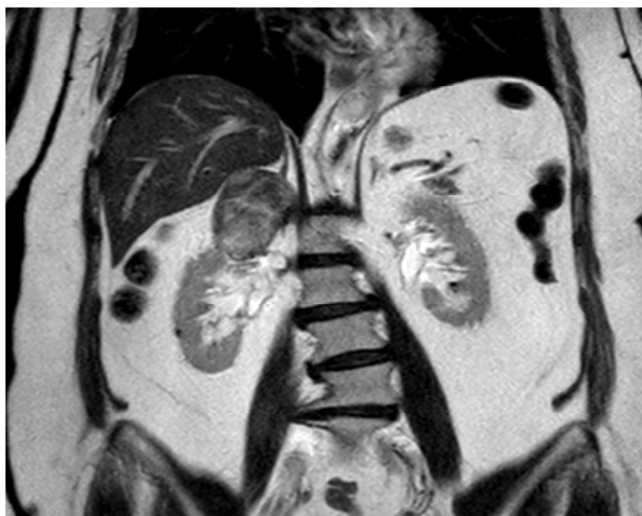


Figure 3: MRI showing size and relations of BIBC adrenal metastases.

Table 1: The frequency of the primary tumor varies depending of the geographical location and the rate of the assessed tumors in a specific population.

Author	Age	Symptoms	Lateralization	Tumor size (cm)	Inmunohistopathology	Disease free interval (years)	Survival after adrenalectomy (years)
Liu et al. 2010	64	Asymptomatic	Left	5.4 x 7.0	Breast: ER-, PR-, HER-2 + Adrenal gland: ER-, PR-, HER-2 +	2	3
Akhtar et al. 2012	45	Abdominal pain Dispnea	Left	2.8 x 2.0	Breast: N.S. Adrenal gland: ER+, PR+, HER-2	1	3
Andjelic-Dekic et al. 2014	58	Asymptomatic	Left	4.8 x 4.76	Breast: ER-, PR-, HER-2 + Adrenal gland: ER+, PR-, HER-2+	3	1
He et al. 2016	35	Asymptomatic	Left	2.6 x 2.8	Breast: N.S. Adrenal gland: ER+, PR+, HER-2+	5	Still under surveillance
Stroescu et al. 2017	66	Abdominal pain	Left	9.0 x 7.0	Breast: ER-, PR-, HER-2- Adrenal gland: N.S.	2	Still under surveillance
Ciriano et al. 2018	64	Asymptomatic	Right	10.0 x 5.5	Breast: ER+, PR+, HER-2 - Adrenal gland: ER+, PR+, HER-2-	10	Still under surveillance

ER: estrogen receptors; PR: progesterone receptors; N.S.: Non specified

Conclusion

In summary, solitary adrenal metastasis of BIBC is an extremely rare finding that should be taken into account in selected clinical situations. This is a case report of an asymptomatic adrenal metastasis diagnosed during follow up of a previously treated patient. According to previous literature, we suggest that in a case of isolated adrenal mass, after image tests and investigation of functional status, adrenalectomy alone or in combination with chemotherapy and/or radiation, is a feasible option. This treatment strategy after confirmation of control of the primary tumor may translate into a better patient prognosis and long-term disease-free survival, as it has been reported in another different malignancies.

On the other hand, and because of the infrequent of this entity, more research and future clinical studies are required to generalize those conclusions to other patients and to clinical practice.

References

- Sancho JJ, Triponez F, Montet X and Sitges-Serra A. Surgical management of adrenal metastases. *Langenbecks Arch Surg.* 2012; 397(2): 179-94.
- McLean K, Lilienfeld H, Caracciolo JT, Hoffe S, Tourtelot JB and Carter WB. Management of Isolated Adrenal Lesions in Cancer Patients. *Cancer Control.* 2011; 18(2): 113-26.
- Lam KY and Lo CY. Metastatic tumours of the adrenal glands: a 30-year experience in a teaching hospital. *Clin Endocrinol.* 2002; 56(1): 95-101.
- Byeon KH, Ha YS, Choi SH, Soo Kim B, Tae Kim H, Sang Yoo E, et al. Predictive factors for adrenal metastasis in extra-adrenal malignancy patients with solitary adrenal mass. *Surg Oncol.* 2018; 118(8): 1271-6.
- Borst MJ and Ingold JA. Metastatic patterns of invasive lobular versus invasive ductal carcinoma of the breast. *Surgery.* 1993; 114(4): 637-42.
- Liu XJ, Shen P, Wang XF, Sun F and Sun FF. Solitary adrenal metastasis from invasive ductal breast cancer: an uncommon finding. *World J Surg Oncol.* 2010; 8: 7.
- Andjelić-Dekić N, Božović-Spašojević I, Milošević S, Matijašević M, Karadžić K. A Rare Case of Isolated Adrenal Metastasis of Invasive Ductal Breast Carcinoma. *SrpArhCelok Lek.* 2014; 142(9-10): 597-601.
- Akhtar K, Sherwani R and Kakhkhashan E. Carcinoma breast metastasis to the suprarenal gland: an unusual presentation. *Pol J Pathol.* 2012; 63: 284-5.
- He T, Liu J, Li Y, Jin L, Sun S, Ni L, et al. Left adrenal gland metastasis of breast invasive ductal carcinoma: A case report. *Mol Clin Oncol.* 2016; 4(5): 859-62.
- Stroescu C, Gilca I, Chirita D, Poenaru R, Puæcaæu A, Pescaru D, et al. Solitary Adrenal Metastases from Breast Invasive Ductal Carcinoma. *Chirurgia.* 2017; 112(4): 473-6.