

Research Article

Open Access, Volume 3

Clinical and Radiographic Results of a Dual-Component Intramedullary Implant for Hammer Toe Deformity in Patients with Rheumatoid Arthritis

Masahiro Tada^{1*}; Toshio Kitano²; Noriaki Hidaka¹

¹Department of Orthopaedic Surgery, Osaka City General Hospital, 2-13-22 Miyakojima-hondori, Miyakojima-ku, Osaka 534-0021, Japan.

²Department of Pediatric Orthopaedic Surgery, Osaka City General Hospital, 2-13-22 Miyakojima-hondori, Miyakojima-ku, Osaka 534-0021, Japan.

Abstract

Objective: Clinical and radiographic results of proximal interphalangeal (PIP) joint arthrodesis using a dual-component intramedullary implant for rheumatoid arthritis (RA) forefoot deformities have not been reported. Thus, the outcomes of this implant were investigated.

Methods: Eleven toes of six RA patients were treated with a dual-component intramedullary implant (Nextra[®] Hammertoe Correction System). Clinical outcomes were assessed by JSSF lesser scale and SAFE-Q score. Radiographic outcomes were evaluated by the alignment and bone fusion of the PIP joint. Patient satisfaction and complications were assessed.

Results: Significant improvements in JSSF lesser score and SAFE-Q score were seen between before and after surgery and maintained until final follow-up. Lateral radiograph alignment of the PIP joint was improved after surgery ($7.6 \pm 2.1^\circ$) compared to that before surgery ($74.1 \pm 18.2^\circ$, $p = 0.001$). All cases showed bone fusion of the PIP joint. Patient satisfaction was relatively high (8.4 ± 1.0 points) after surgery and was maintained until final follow-up (8.6 ± 0.8 points). There were no cases of complications.

Discussion: This is the first study to investigate the clinical and radiographic results of PIP joint arthrodesis by this specific dual-component intramedullary implant for RA forefoot deformity. The advantages of the separate type intramedullary implants are high patient satisfaction in the early postoperative period, early postoperative bone fusion, and reduced risk of infection.

Conclusion: Clinical and radiographic results of PIP joint arthrodesis using this dual-component intramedullary implant for RA forefoot deformity were good. This surgery might be one of the useful methods for hammer toes in RA patients.

Keywords: Hammer toe deformity; Rheumatoid arthritis; PIP joint arthrodesis; Intramedullary implant; Patient satisfaction.

Manuscript Information: Received: Mar 09, 2023; Accepted: Apr 03, 2023; Published: Apr 12, 2023

Correspondance: Masahiro Tada, Department of Orthopaedic Surgery, Osaka City General Hospital, 2-13-22 Miyakojima hondori, Miyakojima, Osaka 534-0021, Japan.

Tel: +81669291221; Email: m-tada@omu.ac.jp

Citation: Tada M, Kitano T, Hidaka N. Clinical and Radiographic Results of a Dual-Component Intramedullary Implant for Hammer Toe Deformity in Patients with Rheumatoid Arthritis. *J Surgery*. 2023; 3(1): 1087.

Copyright: © Tada M 2023. Content published in the journal follows creative common attribution license.

Introduction

Forefoot deformities are relatively common in patients with rheumatoid arthritis (RA). In particular, the prevalence of deformities increases in poorly controlled cases with medium- to long-term disease duration [1]. Hallux valgus, hammer toe, claw toe of the 2nd–4th toes, digitus varus minimi, and flat foot deformity are characteristic deformities of patients with RA [2,3]. In hammer toe, flexion of the proximal interphalangeal (PIP) joint causes dorsal friction by the shoe, resulting in pain and ulceration. In addition, hyperextension of the Metatarsophalangeal (MTP) joint may cause the metatarsal heads to deviate to the plantar side, resulting in painful calluses.

Surgical procedures for hammer toes include flexor digitorum longus tendon transfer [4], shortening osteotomy of the proximal phalanx neck [5], PIP joint arthrodesis [6], and metatarsal shortening osteotomy [7]. Fixation methods for the PIP joint include K-wire or headless screw insertion through the distal phalanx and insertion of an intramedullary implant, either a single-device type or a dual-component type implant. The dual-component type is an interlocking mechanism after insertion of the implant into the metaphyseal and basal phalanges, which simplifies the intraoperative procedure compared to the single-device type intramedullary implant.

We have reported that foot surgery is a risk factor for postoperative infection in RA patients [8]. PIP joint fusion with K-wire fixation increases the infection rate because of the need for wires protruding at the toe end. Implantable devices are preferable. Not only the hammer toe but also the hallux valgus and digitus varus minimi need to be corrected, which increases operative time. Shortening the operative time is also important to decrease the infection rate.

The Nextra[®] Hammertoe Correction System (Zimmer-Biomet, Warsaw, Indiana, USA) is the industry's only adjustable, two-piece, hammer toe solution. The advantage of this implant is its stability, versatility, and anatomic design. It was designed to maximize bone purchase, stabilize and secure the phalanx, and optimize screw design for repeatable outcomes [6]. The two-piece design with the RevLock[®] Adjustable Locking Mechanism provides intermediate locking before final closure and allows for retained compression. The anatomically correct design with 10 degrees of angulation restores the natural state (Figure 1a).

To the best of our knowledge, the clinical and radiographic results of PIP joint arthrodesis by this dual-component intramedullary implant for RA forefoot deformity have not been reported. Thus, the clinical and radiographic outcomes of this implant for hammer toe deformity in patients with RA were investigated.

Materials and methods

Participants

This was a retrospective, observational study to analyze the clinical and radiographic outcomes of a dual-component intramedullary implant for hammer toe deformity in patients with RA. A total of 11 consecutive toes in six patients were treated with the Nextra[®] Hammertoe Correction System between April 2019 and May 2022 and followed-up for at least six months. The research period of this study was between April 2019 and November 2022.

All surgeries were performed by one senior surgeon who was a specialist in foot and ankle surgery at one hospital. The inclusion criteria were as follows: (1) hammer toe deformity; (2) claw toe deformity; or (3) overlapping toe by rheumatoid forefoot. The exclusion criteria were the presence of infection or peripheral vascular disease. Patients stopped biological or targeted synthetic Disease-Modifying Anti-Rheumatic Drugs (DMARDs) and continued conventional synthetic DMARDs during the perioperative period.

In accordance with the Declaration of Helsinki, written, informed consent for participation in the study was obtained from all participants. This study protocol was approved by the institutional review committee of the hospital.

The patients' baseline demographic characteristics are shown in Table 1. The mean age at surgery was 62.6 ± 6.0 (range, 58–72) years, and the mean follow-up duration was 21.0 ± 15.2 (range, 6–43) months. The mean disease duration was 22.7 ± 10.5 years, and most patients had established RA. The Disease Activity Score (DAS) composite of the erythrocyte sedimentation rate (ESR) and the 28-joint score (DAS28-ESR) [9] was 3.38 ± 0.43 , and many patients showed moderate disease activity. The Steinbrocker stage and class were relatively high, and the median modified health assessment questionnaire score was 0.625. Patients were treated with methotrexate (66.7%) and biological or targeted synthetic DMARDs (50%). Two-thirds of the patients were on glucocorticoids, with an average prednisone equivalent dosage of 3.2 ± 1.3 mg. There were no untreated patients. The Larsen grade was 4 and 5 in two and four patients, respectively.

Surgical technique and postoperative procedure

All implants were the dual-component type intramedullary device (Nextra[®] Hammertoe Correction System). PIP joint arthrodesis was performed through a dorsal longitudinal incision, and the extensor tendon was cut at the base of the middle phalanx. The proximal phalanx was osteotomized perpendicular to the plantar surface, and the middle phalanx was osteotomized in plantar flexion of 5 to 10 degrees. A stem hole was reamed at the proximal and middle phalanges, and the implants were fixed with a screwed-in system at each bone. Each implant was connected and confirmed to be locked (Figure 1b). When a gap developed between the bones, bone grafting was performed. The extensor tendon was sutured, and the skin was closed. All surgeries were performed simultaneously with resection arthroplasty (LeLievre method) [10] or joint preservation surgery [11] of the MTP joint.

The forefoot was dressed bulky, and the patients wore orthotics for forefoot unloading to weight-bearing on their heel from one day until two weeks postoperatively. The patients were changed to a functional insole and kept weight-bearing on their heels for eight weeks. Passive range of motion exercises of the ankle joint and toes were permitted from the day after surgery.

Assessment of clinical outcomes

Clinical outcomes at the preoperative, postoperative, and final follow-up visits were evaluated using the Japanese Society for Surgery of the Foot (JSSF) lesser scale [12] and the self-administered foot-evaluation questionnaire (SAFE-Q) score [13]. Patient satisfaction was evaluated after surgery and at final follow-up by a visual analog scale (worst: 0 point, best: 10 points). Complica-

tions, including delayed wound healing, intraoperative fracture, superficial infection, deep infection, and implant removal were assessed and counted.

Assessment of radiographic parameters

Anteroposterior and lateral radiographs of each lesser toe were taken at the preoperative visit and at each follow-up visit. The radiographs were performed in the no-weight-bearing position. The alignment of the PIP joint was defined as the angle between the long axis of the proximal phalanx and the middle phalanx on both anteroposterior (Figure 2a: α angle) and lateral radiographs (Figure 2b: β angle). In the anteroposterior position, varus was defined as + and valgus as -. In the lateral position, flexion was defined as + and extension as -. Bone fusion of the PIP joint was evaluated at the preoperative visit and at each follow-up visit.

Statistical analysis

Continuous data are presented as means \pm standard deviation (SD) for data with a normal distribution or as medians (25th, 75th percentiles) for data not normally distributed. The JSSF scale, SAFE-Q score, and radiographic parameters (α angle and β angle) at pre-operation, post-operation, and final follow-up were compared by the Friedman signed-rank test, with the Bonferroni correction. All statistical tests were two-tailed, and values of $p < 0.05$ were considered significant. All statistical analyses were performed using IBM SPSS Statistics version 26.0 (IBM, Armonk, NY, USA).

Results

Clinical outcomes

The preoperative total JSSF lesser score and subcategory scores were low, as shown in Table 1 and Figure 3. Significant improvements in the total JSSF lesser score and all component scores were seen between pre-operation and post-operation (total score: 31.9 ± 9.0 points vs 82.0 ± 6.3 points, $p = 0.009$), and the significant improvements were maintained until final follow-up (total score: 86.0 ± 6.8 points, $p < 0.001$). The SAFE-Q scores were significantly higher at post-operation and final follow-up than at pre-operation (all $p < 0.001$), as shown in Table 2. Shoe-related points were relatively lower than other points at all times.

Patient satisfaction at post-operation was relatively high (8.4 ± 1.0 points) and maintained until final follow-up (8.6 ± 0.8 points).

Radiographic outcomes

Radiographic results are shown in Figure 4. The α angles were improved at post-operation ($2.5 \pm 3.9^\circ$) and final follow-up ($2.1 \pm 4.3^\circ$) compared to pre-operation ($9.1 \pm 9.4^\circ$) ($p = 0.128$, $p = 0.043$, respectively). The β angle also improved at post-operation ($7.6 \pm 2.1^\circ$) compared to pre-operation ($74.1 \pm 18.2^\circ$, $p = 0.001$) and was maintained until final follow-up ($7.8 \pm 2.1^\circ$, $p = 0.003$). All cases showed bone fusion of the PIP joint at six months postoperatively.

Complications

There were no cases of delayed wound healing, intraoperative fracture, superficial infection, deep infection, or implant removal by the time of final follow-up.

Table 1: Rheumatoid arthritis patients' baseline demographic characteristics.

| | 6 RA patients, 11 lesser toes |
|----------------------------------|-------------------------------|
| Age, year | 62.6 \pm 6.0 |
| Men: Women, n | 01:05 |
| BMI, kg/m ² | 22.1 \pm 2.8 |
| Disease duration, years | 22.7 \pm 10.5 |
| Follow-up duration, months | 21.0 \pm 15.2 |
| DAS28-ESR | 3.38 \pm 0.43 |
| mHAQ | 0.625 (0.5, 0.75) |
| Steinbrocker stage | IV:6 |
| Steinbrocker class | 2:3, 3:3 |
| CRP, mg/dl | 0.09 (0.08, 0.14) |
| MMP3, ng/ml | 67.4 (57.2, 82.0) |
| RF positive, % | 83.3 |
| Methotrexate, mg/week, rate (%) | 7.0 \pm 1.2 (66.7) |
| Glucocorticoid, mg/day, rate (%) | 3.2 \pm 1.3 (66.7) |
| bDMARDs or tsDMARDs rate, % | 50 |
| JSSF lesser scale total, points | 31.9 \pm 9.0 |
| Pain, points | 16.4 \pm 8.1 |
| Function, points | 15.5 \pm 3.3 |
| Alignment, points | 0 \pm 0 |
| Larsen grade | 4:2, 5:4 |

Data are shown as means \pm standard deviation (SD) for those with a normal distribution or as medians (25th, 75th percentiles) for those not normally distributed.

RA: Rheumatoid arthritis; BMI: Body Mass Index; DAS: disease activity score; ESR: Erythrocyte Sedimentation Rate; mHAQ : Modified Health Assessment Questionnaire; CRP: C-Reactive Protein; MMP3: Matrix Metalloproteinase 3; RF: Rheumatoid Factor; bDMARDs: Biological Disease-Modifying Antirheumatic Drugs; tsDMARDs: Targeted Synthetic Disease-Modifying Antirheumatic Drugs; JSSF: Japanese Society for Surgery of the Foot.

Table 2: SAFE-Q scores at pre-, post-operation, and final follow-up.

| | Pre-operation | Post-operation | Final follow-up |
|----------------------------|-----------------|------------------|------------------|
| Pain, points | 52.6 \pm 21.6 | 89.5 \pm 8.3* | 89.5 \pm 8.3* |
| Physical functions, points | 48.4 \pm 18.3 | 82.9 \pm 12.7* | 82.8 \pm 12.7* |
| Social functioning, points | 40.5 \pm 28.2 | 80.2 \pm 21.8* | 80.2 \pm 21.8* |
| Shoe related, points | 16.7 \pm 6.5 | 65.1 \pm 11.7* | 67.4 \pm 10.8* |
| General health, points | 25.5 \pm 12.5 | 84.1 \pm 13.8* | 85.5 \pm 14.0* |

Data are shown as means \pm standard deviation (SD).

Continuous variables were analyzed using the Friedman signed-rank test, adjusted Bonferroni.

*: $p < 0.001$ compared with the pre-operation score.

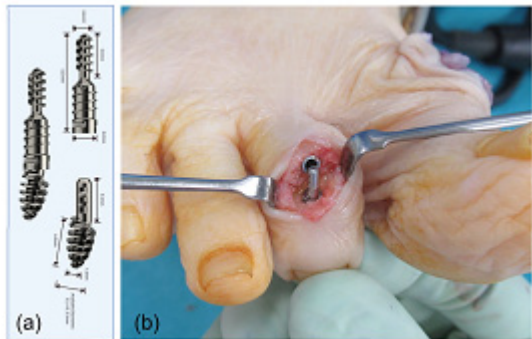


Figure 1: The Nextra® Hammertoe Correction System (a). This unique implant is a dual-component type intramedullary implant that has the RevLock® Adjustable Locking Mechanism. After the implants are fixed with the screwed-in system at the middle phalanx and the proximal phalanx of the right second toe, the implants are locked to each other (b).

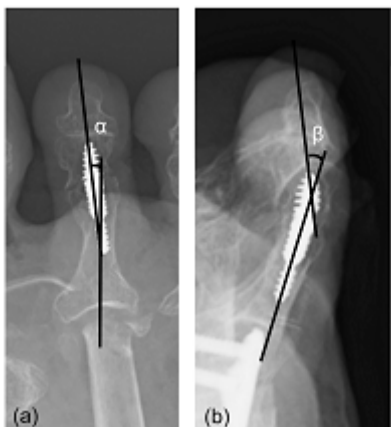


Figure 2: The evaluation of the alignment of PIP joint. No-weight-bearing anteroposterior (a) and lateral (b) radiographs. The α angle (a) and β angle (b) are defined as the angles between the long axes of the proximal phalanx and the middle phalanx on the anteroposterior and lateral radiographs, respectively.

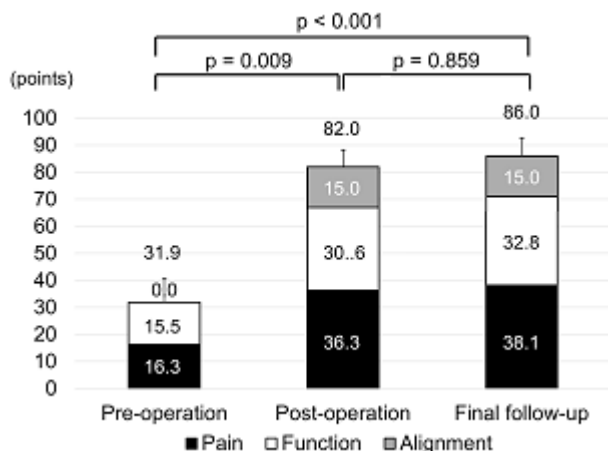


Figure 3: The JSSF lesser total and component scale scores obtained at pre-operation, post-operation, and final follow-up. Total and all component scale scores are significantly improved at post-operation and maintained until final follow-up. Values are given as means and analyzed by the Freidman signed-rank test, with the Bonferroni correction.

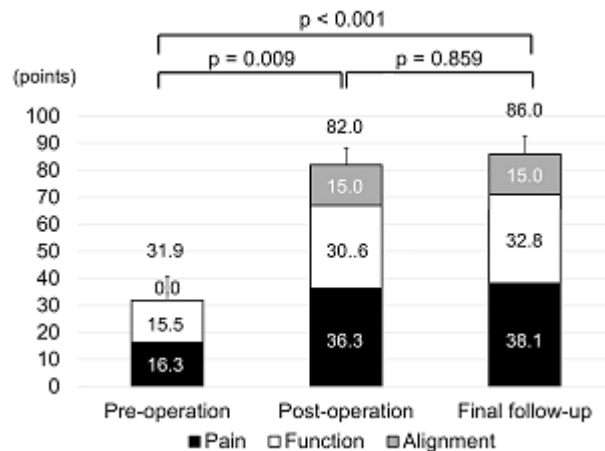


Figure 4: The radiographic outcomes obtained at pre-operation, post-operation, and final follow-up. The α angle (anteroposterior alignment) (a) and the β angle (lateral alignment) (b) are closer to neutral at post-operation and maintained until final follow-up. Values are given as means and analyzed by the Freidman signed-rank test, with the Bonferroni correction.

Discussion

This is the first study to investigate the clinical and radiographic results of PIP joint arthrodesis by this specific dual-component intramedullary implant for RA forefoot deformity. Strong initial fixation was obtained, and bone fusion was achieved in all cases by the interlocking mechanism of the Nextra® Hammertoe Correction System. Jay et al. reported the advantage of this system [6]. The surgeon can seat the proximal and middle phalangeal components of the 2-piece implant to the desired level in each ossicle, thereby creating bone-to-bone contact as soon as the implant components are coupled. The degree of bone-to-bone contact remains constant thereafter, because each component of the implant is screwed into the corresponding phalanx and, as such, cannot piston, rotate, or flex. Witt et al. described the characteristics of intramedullary fixation devices as resistance to flexion, rotation, and pistoning, those that effect interfragmental compression, and those that are not simply round in the cross-section [14].

In a systematic review comparing intramedullary implants and K-wires, the only benefit of intramedullary implants was the bone fusion rate, with no significant differences in pain relief, patient satisfaction, function, or complication rates [15]. On the other hand, in a randomized, controlled trial comparing clinical scores and bone healing of separate type intramedullary implants (47 toes) and K-wires (45 toes), patient satisfaction at one week postoperatively and early bone healing were significantly better with the separate type intramedullary implant than with the K-wires [6]. Patient satisfaction with the intramedullary implant was due to the fact that the wire did not protrude from the phalangeal apex, which allowed for early bathing and the ability to wear shoes. The bone-to-bone contact caused by crimping through a locking mechanism was also a factor in the good bone fusion.

The advantages of the separate type intramedullary implants are high patient satisfaction in the early postoperative period, early postoperative bone fusion, and reduced risk of infection, whereas the disadvantages are difficulty in removal due to infection and high cost.

RA patients are at higher risk of postoperative infection than osteoarthritis patients [16]. In RA patients, foot and ankle surgery is reported to have a higher risk of infection than that of other sites [8,17]. In addition, osteoporosis is a complicating factor that leads to poor initial fixation and delays bone healing. These considerations make dual-component type intramedullary implants potentially more useful than K-wire fixation and single-device type intramedullary implants.

The present study has several limitations that must be considered. First, the sample size was small, because metatarsal shortening osteotomy and resection arthroplasty have been mainly performed for hammer toe in RA patients. Second, bone fusion was determined only by radiography, with no CT performed. Third, there was no comparison with K-wire fixation or single-device type intramedullary implants. Finally, the follow-up periods were too short to evaluate the longevity of the dual-component intramedullary implant. A longer follow-up period is necessary to investigate the clinical and radiographic results in the future.

Conclusions

The present study showed the clinical and radiographic results of PIP joint arthrodesis by a specific dual-component intramedullary implant for RA forefoot deformity. Anteroposterior and lateral alignments of the PIP joint on radiography were improved at post-operation and maintained until final follow-up. There were no cases of delayed wound healing, intraoperative fracture, superficial infection, deep infection, or implant removal by the time of final follow-up. Patient satisfaction was high. The PIP joint arthrodesis with dual-component intramedullary implant might be one of the useful methods for hammer toes in patients with RA.

Funding: None.

Conflict of interest statement: All authors declare no conflict of interest.

Data availability: The datasets used and/or analyzed during the current study are available from the corresponding author on reasonable request.

References

1. Michelson J, Easley M, Wigley FM, Hellmann D. Foot and ankle problems in rheumatoid arthritis. *Foot Ankle Int.* 1994; 15: 608-613.
2. Yano K, Ikari K, Iwamoto T, Saito A, Naito Y, et al. Proximal rotational closing-wedge osteotomy of the first metatarsal in rheumatoid arthritis: clinical and radiographic evaluation of a continuous series of 35 cases. *Mod Rheumatol.* 2013; 23: 953-958.
3. Tada M, Koike T, Okano T, Sugioka Y, Wakitani S, et al. Preference of surgical procedure for the forefoot deformity in the rheumatoid arthritis patients--A prospective, randomized, internal controlled study. *Mod Rheumatol.* 2015; 25: 362-366.
4. DiPaolo ZJ, Ross MS, Laughlin RT, Gould G, Flower K, et al. Proximal phalanx and flexor digitorum longus tendon biomechanics in flexor

to extensor tendon transfer. *Foot Ankle Int.* 2015; 36: 585-590.

5. Ceccarini P, Rinonapoli G, Sebastiani E, Bisaccia M, Ceccarini A, et al. Clinical Comparison Between Shortening Osteotomy of the Proximal Phalanx Neck and Arthrodesis in Hammer Toe Surgery at Mid-Term Follow-Up. *J Foot Ankle Surg.* 2019; 58: 221-225.
6. Jay RM, Malay DS, Landsman AS, Jennato N, Huish J, et al. Dual-Component Intramedullary Implant Versus Kirschner Wire for Proximal Interphalangeal Joint Fusion: A Randomized Controlled Clinical Trial. *J Foot Ankle Surg.* 2016; 55: 697-708.
7. Hofstaetter SG, Hofstaetter JG, Petroutsas JA, Gruber F, Ritschl P, et al. The Weil osteotomy: a seven-year follow-up. *J Bone Joint Surg Br.* 2005; 87: 1507-1511.
8. Tada M, Inui K, Sugioka Y, Mamoto K, Okano T, et al. Delayed wound healing and postoperative surgical site infections in patients with rheumatoid arthritis treated with or without biological disease-modifying antirheumatic drugs. *Clin Rheumatol.* 2016; 35: 1475-1481.
9. Prevoe ML, van 't Hof MA, Kuper HH, van Leeuwen MA, van de Putte LB, et al. Modified disease activity scores that include twenty-eight-joint counts. Development and validation in a prospective longitudinal study of patients with rheumatoid arthritis. *Arthritis Rheum.* 1995; 38: 44-48.
10. LeLièvre J. The pathology of the Foot. Physiology and Clinical Aspects and Medical, Orthopaedic and Surgical Treatment. Paris: Masson et Cie. 1961.
11. Hanyu T, Yamazaki H, Murasawa A, Tohyama C. Arthroplasty for rheumatoid forefoot deformities by a shortening oblique osteotomy. *Clin Orthop Relat Res.* 1997; 131-138.
12. Niki H, Aoki H, Inokuchi S, Ozeki S, Kinoshita M, Kura H, et al. Development and reliability of a standard rating system for outcome measurement of foot and ankle disorders I: development of standard rating system. *J Orthop Sci.* 2005; 10: 457-465.
13. Niki H, Tatsunami S, Haraguchi N, Aoki T, Okuda R, et al. Validity and reliability of a self-administered foot evaluation questionnaire (SAFE-Q). *J Orthop Sci.* 2013; 18: 298-320.
14. Witt BL, Hyer CF. Treatment of hammertoe deformity using a one-piece intramedullary device: a case series. *J Foot Ankle Surg.* 2012; 51: 450-456.
15. Wei RX, Ling SK, Lui TH, Yung PS. Ideal implant choice for proximal interphalangeal joint arthrodesis in hammer toe/claw toe deformity correction: A systematic review. *J Orthop Surg (Hong Kong).* 2020; 28: 2309499020911168.
16. Cordtz R, Odgaard A, Kristensen LE, Overgaard S, Dreyer L. Risk of medical complications following total hip or knee arthroplasty in patients with rheumatoid arthritis: A register-based cohort study from Denmark. *Semin Arthritis Rheum.* 2020; 50: 30-35.
17. Kadota Y, Nishida K, Hashizume K, Nasu Y, Nakahara R, et al. Risk factors for surgical site infection and delayed wound healing after orthopedic surgery in rheumatoid arthritis patients. *Mod Rheumatol.* 2016; 26: 68-74.