

Case Series

Open Access, Volume 3

Giant Bladder Calcium Lithiasis: A Rare Clinical Presentation

Mohamed Jalloh*; Kamal Abdel Aziz; Medina Ndoeye; Mouhamadou M Mbodji; Abdourahmane Diallo; Ngor M Thiam; Oumar Gaye; Lamine Niang; Serigne M Gueye

Hopital General Idrissa Pouye and Université Cheikh Anta Diop de Dakar, Senegal.

Abstract

The incidence of uro lithiasis is increasing with higher proportion of calcium lithiasis. While the large majority of lithiasis are formed in the kidney before migrating in the urinary tract, certain lithiasis are formed in the bladder owing to local factors. We report 2 cases of giant bladder lithiasis in patients presenting lower urinary tract obstruction. A review of the literature was performed to discuss these clinical presentations.

Keywords: Giant bladder lithiasis; Cystolithotomy; Calcium lithiasis.

Introduction

Urinary lithiasis is defined by stony concretion in the urinary tract. In recent decades the incidence of urinary lithiasis is regularly increasing. In the United States, it is estimated that 11% of men and 5.6% of women will have experienced urinary lithiasis by the age of 70 years with a 3-fold higher risk in Caucasian compared to African American [1]. More than 80% of these lithiasis are of calcium nature, essentially oxalo-calcic. Although the mechanisms of stone formation are well clarified by a good understanding of lithogenesis [2], the site of stone formation is also very important [3]. Papillary biopsies show differences in the site of crystal deposits based on the nature of the lithiasis. Idiopathic calcium oxalate crystals are formed in interstitial areas containing calcium phosphate crystals at the level of Randall's plaques of papillary surface [3], while calcium phosphate crystals are associated with internal deposits of apatite or a mixture of other crystals in the collecting system of the medullary [4].

Bladder localization represents 5% of all urinary tract lithiasis [5], they develop over many years and have varying sizes [6]. This explains why giant bladder lithiasis are very rare. In men, urinary

bladder stasis secondary to lower urinary tract obstruction and neurogenic bladder are the main factors promoting bladder stone formation [6]. Bladder lithiasis can be latent for a long period as opposed to upper tract lithiasis causing pain. In the period 2006-2018, it is reported that 11 million patients suffering from urolithiasis benefitted from opioid therapy [7].

The aim of our study was to report 2 cases of giant bladder calcium lithiasis to present the clinical presentation, etiologic factors and treatment and to perform a review of the literature to explain the origin of this type of lithiasis compared to upper urinary tract lithiasis.

Case presentation #1

Mr M.A, is a 70 years old man, university faculty living in urban area, with a history of surgery for cataract referred in April 2020 for chronic urinary retention. He reported a long history of difficulty passing urine prior to a urinary retention that occurred in November 2019 in France at which time a trans urethral Foley catheter was placed and changed on the regular basis.

Manuscript Information: Received: Mar 16, 2023; Accepted: Apr 19, 2023; Published: Apr 26, 2023

Correspondance: Mohamed Jalloh, Service d'Urologie, Hopital General Idrissa Pouye, Dakar, Senegal.

Email: jmohamed60@yahoo.fr

Citation: Jalloh M, Aziz KA, Ndoeye M, Mbodji MM, Diallo A. Giant Bladder Calcium Lithiasis: A Rare Clinical Presentation. *J Surgery*. 2023; 3(1): 1092.

Copyright: © Jalloh M 2023. Content published in the journal follows creative common attribution license.

Physical examination found a patient in good general condition (WHO I), a distended bladder up to level of the umbilicus, trans urethral Foley catheter was in place draining purulent urines. Digital rectal examination found an enlarged, firm, regular and painless prostate without the median groove. There was no fever.

The patient was immediately admitted, the Foley catheter was replaced by a 3-way Foley catheter, a progressive drainage was performed with bladder irrigation by saline.

Blood cell count showed 13,700 white blood cell/ μ L with a predominance of neutrophils and a hemoglobin concentration of 9.7 g/dl. CRP level was 140,5 mg/L, creatinine level was 67,8 mg/L and serum electrolytes level was normal. Urine culture diagnosed a urinary infection by Klebsiella Pneumonia sensitive only to amikacin, the patient subsequently underwent half dose of amikacin over 4 days due to the renal failure. Ultrasound examination showed a prostatic volume of 51 ml and a bilateral ureteral and kidney dilatation with good corticoinusal differentiation.

He underwent a cystolithotomy removing a giant lithiasis measuring 10 X 8 cm and weighing 581 g. The lithiasis was yellowish and friable (Figure 1).

Post-operative course was marked by vesico cutaneous fistulae managed by prolonged drainage and regular dressing change. The lithiasis was examined by spectrophotometry and infra-red showing a composition of calcium oxalate (87%), calcium (10%) and phosphor (3%). Trans Urethral resection of the prostate was planned subsequently.

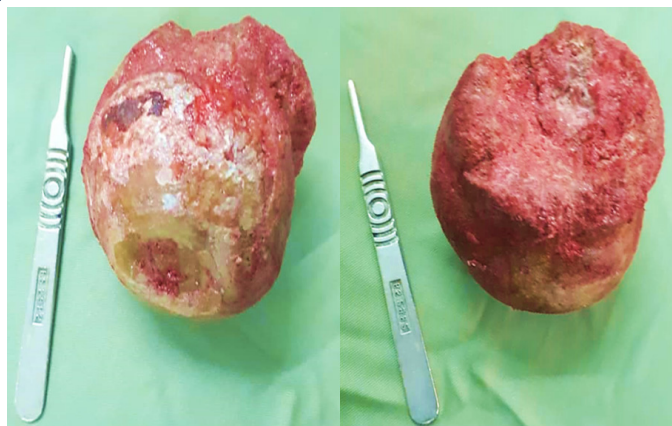


Figure 1: Post-operative image of a giant bladder lithiasis.

Case presentation #2

Mr T.P is a 65 years old man with a history of car accident in 1993 causing head trauma and coma. He was then admitted for 2 weeks in Intensive care unit with an indwelling Foley catheter. He was referred to Urology department in September 2020 for urinary retention preceded by a long period of difficulty passing urine.

At examination the patient had a poor general condition (WHO 3), a distended bladder reaching the umbilicus, an enlarged prostate of benign appearance at digital rectal examination. The rest of the clinical examination was normal.

An attempt to place a Foley catheter stuck in the urethra and an attempt to place a suprapubic tube faced a very hard mass in

the bladder.

Laboratory work found a creatinine level of 142.8 mg/l, hyperkalemia (5,9 meq/L) and urine culture diagnosed an infection by Klebsiella Pneumonia sensitive to chloramphenicol and amikacin and the patient underwent antibiotic treatment. Ultrasonography found a thickened bladder wall containing a giant lithiasis with an important dilatation of both ureters and kidneys and a prostatic volume of 67 ml. CT Scan without injection of contrast medium confirmed the findings of ultrasonography and indicated a bladder lithiasis measuring 98x90x167 mm in size (Figure 2).

The patient immediately underwent a cystotomy showing a giant lithiasis occupying all the bladder, hard, yellowish and weighing 1517 g (Figure 3). A suprapubic tube was placed to drain the urines given the urethral stenosis.

Post-operative course was uneventful with a wound healing without infection or fistula. The patient general condition improved and the creatinine and potassium levels became normal at one-month post op. Spectrophotometric infra-red examination of the lithiasis found a 100% phosphor calcic composition. The patient was ordered to perform retrograde cystography to study the urethral stricture but he was lost to follow-up.

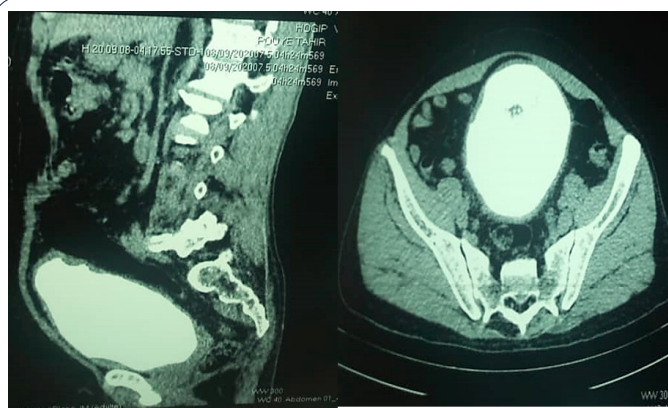


Figure 2: CT Scan showing a giant lithiasis occupying the whole bladder.

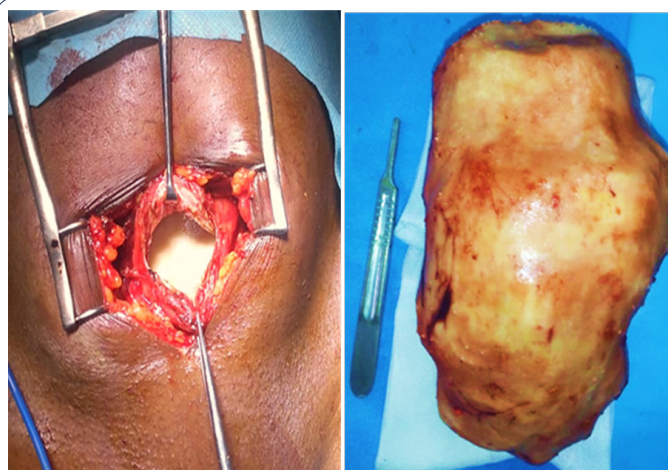


Figure 3: Per operative (Left) and post-operative image of a giant bladder lithiasis.

Discussion

Bladder lithiasis poses a problem of its origin, most lithiasis are formed in the kidneys and migrate into the ureters and bladder [3]. Local factors can then promote lithiasis growth. But the bladder can be the initial site of lithiasis development mostly in case of urinary stasis, like in our 2 cases. This is common in lower urinary tract obstructions that cause post voiding bladder residue and subsequently lithogenesis is initiated in the bladder [4]. Our two patients presented an obstruction, the first one had a benign prostatic hyperplasia complicated by urinary retention and the second patient developed a urethral stricture secondary to a Foley catheter placement in a context of coma. Apart from lower urinary tract obstruction, neurogenic bladder is another important cause of bladder urinary stasis that can promote in situ lithiasis formation [4].

In our cases the composition of the lithiasis was essentially made of calcium. Such findings are in accordance with the reported predominance of calcium lithiasis with a proportion of at least 80% [2], this includes oxalocalcic and phosphocalcic lithiasis. However, Douenias R et al. reported a predominance of uric acid lithiasis in bladder stones [6]. Urinary infection is often associated with bladder stasis which in turn is a factor of urolithiasis formation. Infected urines by germs from the lithiasis can secondarily cause post-operative wound infection and vesico cutaneous fistulae. Our first case experienced such a complication.

Although factors of lithogenesis in the bladder are mainly stasis and infection, the mechanism of lithiasis growth to the stage of giant size remains to be explained. Delay in consultation in spite of lower urinary tract symptoms is one of the key reasons especially because the bladder has the largest storing capacity of the urinary tract segments allowing for a longer evolution of the disease conducive for lithiasis growth. Prolonged stasis due to the bladder outlet obstruction contributes to the progressive growth of the lithiasis.

Symptoms suggesting bladder lithiasis are dominated by suprapubic pain, dysuria, hematuria, difficulty passing urine and irritative symptoms [8], however the condition can be asymptomatic. Our two patients presented urinary retention given the big size of the lithiasis and the underlying lower urinary tract obstruction.

Treatment consists of surgical ablation of the lithiasis and the treatment of underlying condition. Our patients underwent open cystolithotomy that will be followed by trans urethral prostatic resection in the first case and urethral reconstruction in the second case after urethral imaging. Our surgical approach is similar to the case report of Shrestha et al. [8] who removed a 950 g lithiasis in a patient with no lower urinary tract obstruction or neurogenic bladder. Other small size bladder lithiasis can be managed by a variety of mini invasive endoscopic techniques: ultrasound, electrohydraulic, Holmium: YAG laser... [10].

Global bladder lithiasis management must also include prevention of recurrence taking into account the treatment of the etiology, the composition of the lithiasis and the metabolic characteristics of the patients [11]. It is also important to treat urinary infection that can promote bladder lithiasis [12].

Conclusion

Giant bladder lithiasis are rare and often secondary to neglected lower urinary tract disorders causing a stasis. Lithiasis formation and growth can occur within many years and can be favored by delay in referral and lack of exploration. In the setting of chronic bladder outlet obstruction, imaging should be performed to search for lithiasis complication and treat both the lithiasis and the obstruction.

Références

1. Stamatelou KK, Francis ME, Jones CA, Nyberg LM Jr, Curhan GC. Time trends in reported prevalence of kidney stones in the United States:1976–1994. *Kid Int.* 2003; 63: 1817-1823.
2. Worcester EM, Coe FL, Elaine M. *Clinical Practice Calcium Kidney Stones.* *N Engl J Med.* 2010; 363: 954-963.
3. Miller NL, Gillen DL, Williams JC. A formal test of the hypothesis that idiopathic calcium oxalate stones grow on Randall's plaque. *BJU Int.* 2009; 103: 966-971.
4. Douenias R, Rich M, Badlani G, Mazor D, Smith A. Predisposing factors in bladder calculi. Review of 100 cases. *Urology.* 1991; 37: 240-243.
5. Schwartz BF, Stoller ML. The vesical calculus. *Urol Clin North Am.* 2000; 27: 333-346.
6. Torricelli FC, Mazzucchi E, Danilovic A, Coelho RF, Srougi M. Surgical management of bladder stones: literature review. *Rev Col Bras Cir.* 2013; 40: 227-233.
7. Zhu D, Macdonald EJ, Lesko RP, Watts KL. National trends and prescription patterns in opiate analgesia for urolithiasis presenting to Emergency Departments: Analysis of the National Hospital Ambulatory Medical Care Survey, 2006-2018. *Urology.* 2021; S0090-4295(21)01173-0.
8. Papatsoris AG, Varkarakis I, Dellis A, Deliveliotis C. Bladder lithiasis: from open surgery to lithotripsy. *Urol Res.* 2006; 34: 163.
9. Shrestha N, Zhou L, Hu CH. Extraction of giant bladder calcium oxalate stone: A case report. *Int J Surg Case Rep.* 2020; 68: 151-153.
10. Papatsoris AG, Varkarakis I, Dellis A, Deliveliotis C. Bladder lithiasis: from open surgery to lithotripsy. *Urol Res.* 2006; 34: 163-167.
11. Porena M, Guiggi P, Micheli C. Prevention of stone disease. *Urol Int.* 2007; 79: 37-46.
12. Mohamed AH, Yasar A, Mohamud HA. Giant bladder stone of 152g in an 11-year child with recurrent urinary tract infections: A rare case report and review of the literature. *Urol Case Rep.* 2021; 38: 101676.