

Case Report

Open Access, Volume 3

Amyand's Hernia with Perforated Appendicitis Presenting as Strangulated Hernia: A Rare Case Report

Nur Ameera Mohd Nadzrin*; Mohd Azihan Zahari

General Surgery Department, Hospital Teluk Intan, Perak, Malaysia.

Abstract

An inguinal hernia is one of the most common surgical conditions accounting for both elective and emergency cases. Amyand's hernia is a rare entity and is often an incidental intraoperative finding but may present as strangulation or appendicitis in the hernia sac. It is commonly not identified preoperatively as patients may present as strangulated inguinal hernia, which warrants emergency surgery rather than imaging, such as a CT scan or ultrasound. We report a case of Amyand's hernia in an 84 years-old man who presented with a tender and swollen right inguinal mass, who was diagnosed as strangulated right inguinal hernia and underwent emergency surgical exploration.

Keywords: Amyand's; Hernia; Inguinal.

Introduction

The most common type of abdominal wall hernia is inguinal hernia, which accounts for about 75% [1]. Amyand's hernia is the presence of a normal or inflamed vermiform appendix inside an inguinal hernia sac. It is named in honour of the surgeon Claudius Amyand who performed the first appendectomy of an appendix located in the inguinal canal after a child swallowed a pin causing appendicitis in 1735 [2]. Amyand's hernia may be inflamed, incarcerated, perforated or completely healthy. Logan MT [3] reported that the incidence of appendix as an inguinal hernia sac content is less than 1%. The diagnosis of Amyand's hernia is three-fold higher in the pediatric population due to patent precessus vaginalis [4]. The mortality rate of Amyand's hernia can reach 30%, most commonly attributed to peritoneal spread of sepsis [5]. Although Amyand's hernia usually occurs on the right side, according to the normal anatomical position of appendix, it can appear on the left

side in situs inversus, gut malrotation and mobile cecum [6]. The peculiarity of its clinical signs and symptoms together with the inadequate radiological features of Amyand's hernia make its diagnosis difficult pre-operatively, it is almost always found intraoperatively.

Case report

An 84 years-old man with underlying gout, hypertension and benign prostatic hyperplasia presented with painful right inguinal swelling associated with abdominal distension and no bowel output for 3 days. He denied fever and vomiting. Upon arrival to the casualty, he was hemodynamically stable. On clinical examination, abdomen was soft, slightly distended. There was an irreducible right inguinal swelling measuring approximately 4x4cm, tender on palpation with no skin changes. Bilateral testes and scrotal examinations were normal. Digital rectal examina-

Manuscript Information: Received: Apr 25, 2023; Accepted: May 19, 2023; Published: May 29, 2023

Correspondance: Nur Ameera Mohd Nadzrin, General Surgery Department, Hospital Teluk Intan, 1515, Jalan Emas 1, Taman Bandar Baru, 31900 Kampar, Perak, Malaysia.

Email: nurameera.tusc@gmail.com

Citation: Nadzrin NAM, Zahari MA. Amyand's Hernia with Perforated Appendicitis Presenting as Strangulated Hernia: A Rare Case Report. *J Surgery*. 2023; 3(1): 1104.

Copyright: © Mohd Nadzrin NA 2023. Content published in the journal follows creative common attribution license.

tion was empty. Blood parameters showed no signs of infection, however his venous blood gas was mildly acidotic. His chest X-ray was normal. Abdominal X-ray revealed nonspecific large and small bowel dilatation. He was given adequate fluid resuscitation. With a preoperative provisional diagnosis of strangulated right inguinal hernia, the patient underwent right inguinal exploration. Intraoperatively noted there was localized seropurulent collection in the sac with edematous and inflamed appendix. Appendix base was difficult to visualize, thus proceeded with a lower midline laparotomy which revealed perforated appendix near its base.

There was no incarceration or adhesion, cord structures were normal and preserved.

Appendectomy with lavage was done followed by herniotomy and herniorraphy using modified Bassini's repair. Abdominal and inguinal incisions were closed without mesh placement. Postoperatively, the patient had an uneventful recovery and was discharged after 2 days with oral antibiotics. During follow-up a month later, he was well with no recurrence. Histopathological examination revealed perforated appendicitis.

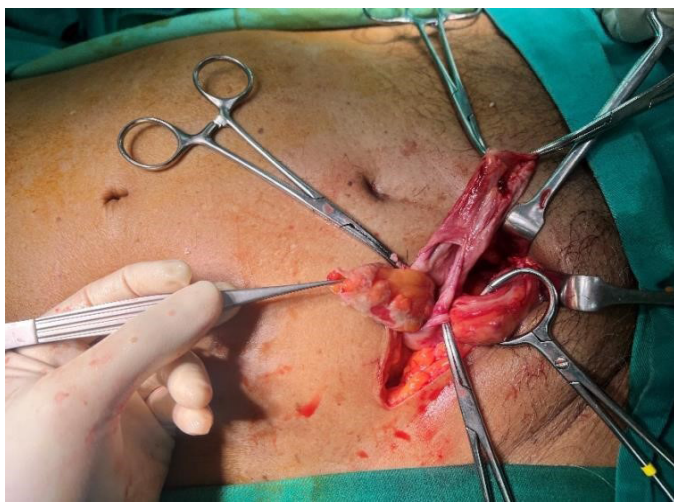


Figure 1: Right inguinal hernia sac contains appendix which appears inflamed and edematous. Previous suprapubic catheterization scar is visible.

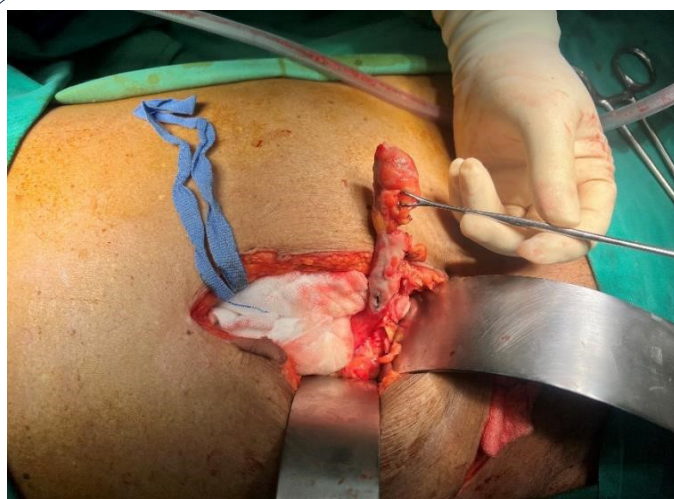

Figure 2: Lower midline laparotomy was performed, noted perforated appendix near its base.

Discussion

Many theories have been postulated for the occurrence of Amyand's hernia. Long appendix pointing towards the groin, loose peritoneal reflections and redundant cecum causes the appendix to reach and gets retained in the hernia sac [7]. The pathophysiology of Amyand's hernia remains controversial. Studies indicated that muscle contractions and sudden rise in intrabdominal pressure may compress the appendix in the external ring. This compromises its blood flow resulting in recurrent inflammation and bacterial overgrowth. Besides that, an extraluminal obstruction causes edematous appendix due to narrowing of hernia neck [8]. Unlike other inguinal hernia with bowel content, Amyand's hernia may appear without signs of obstruction and inflammatory markers stay within normal limits. Various complications may arise from Amyand's hernia such as perforated appendix with periappendicular or intraabdominal abscess, necrotizing fasciitis of the anterior abdominal wall, epididymo-orchitis or testicular abscess, and in-situ arterial thrombosis in rare occurrence [9]. The most common treatment modality is appendectomy via herniotomy with primary hernia repair without mesh application. Lower midline laparotomy is advocated in perforation, pelvic abscess or when other abdominal pathologies are encountered. Laparoscopic appendectomy in case of Amyand's hernia with appendicitis was first reported by Vermillion et al [8]. Multiple debates arise as to whether to remove the appendix if it's normal and mesh application. While some argued that appendectomy should be done if evidence of inflammation, others supported appendectomy in non-inflamed appendix to avoid future complications. The mere manipulation of a healthy appendix may provoke inflammation resulting in secondary appendicitis [10-12]. Appendectomy of a healthy appendix is considered not necessarily beneficial as transection of a fecal-containing organ in a clean surgery increases septic complications. Besides that, removal of appendiceal lymphoid tissue may compromise the pediatric patient's immune development [12]. It is generally accepted that the use of mesh in hernia repair in contaminated wounds is strongly opposed due to the high risk of surgical site infection. However, several studies reported the use of mesh repair and adequate antibiotic coverage without infection rate increments [13]. Biosynthetic meshes may have a role in these, but they are not readily available. Ultimately, the surgical decision is in the surgeon's hands, the aim is to have a lower risk of surgical site infection than the risk of hernia recurrence. This debate led Losanoff and Basson [14] to propose a classification system for the principal of management of Amyand's hernia based on appendix state, presence of abdominal sepsis and concomitant abdominal pathology. Type 1 is a normal appendix in an inguinal hernia, to perform hernia reduction and mesh placement. Type 2 is acute appendicitis localized in the hernia sac, to perform appendectomy with primary hernia repair. Type 3 is acute appendicitis complicated with peritonitis, to perform laparotomy, appendectomy and primary hernia repair. Type 4 is acute appendicitis with concomitant abdominal pathology, its management is similar as type 3 with management of concomitant disease.

Conclusion

Amyand's hernia may sometimes lead to serious and life-threatening complications, thus needs to be handled with utmost vigilance. As it is commonly identified intraoperatively, every sur-

geon should be prepared to cope with such an unexpected situation and to proceed with the most suitable surgical modality for an excellent outcome.

References

1. Kingsnorth A, LeBlanc K. Hernias: Inguinal and incisional," *The Lancet*. 2003; 362: 1561-1571.
2. Sengul I., Sengul D, Aribas D. An elective detection of an Amyand's hernia with an adhesive caecum to the SAC: Report of a rare case," *North American Journal of Medical Sciences*. 2011; 391-393.
3. JM;, L.M.T.N. Amyand's hernia: A case report of an incarcerated and perforated appendix within an inguinal hernia and review of the literature, *The American surgeon*. U.S. National Library of Medicine.
4. Baldassarre. Amyand's hernia in Premature twins," *Hernia*. 2008;13: 229-230.
5. D'Alia C. Amyand's hernia: Case report and review of the literature," *Hernia*. 2003; 7: 89-91.
6. R;, G.S.S.R.K. Left-sided Amyand's hernia, *Singapore medical journal*. U.S. National Library of Medicine.
7. Barut İ, Tarhan ÖR. A rare variation of amyand's hernia: Gangrenous appendicitis in an incarcerated inguinal hernia sac," *Electronic Journal of General Medicine*. 2008; 5: 112-114.
8. Solecki R, Matyja A, Milanowski W. Amyand's hernia: A report of two cases," *Hernia*. 2003; 7: 50-51.
9. Desai G, Suhani, Pande P, Thomas S. AMYAND'S HERNIA: OUR EXPERIENCE AND REVIEW OF LITERATURE. *Arq Bras Cir Dig*. 2017; 30: 287-288.
10. PMC5793150.Cankorkmaz L. Amyand's hernia in the children: A single center experience," *Surgery*. 2010; 147: 140-143.
11. Cankorkmaz L. Amyand's hernia in the children: A single center experience," *Surgery*. 2010; 147: 140-143.
12. Burgess PL, Brockmeyer JR, Johnson EK. Amyand hernia repaired with bio-A: A case report and review. *Journal of Surgical Education*. 2011; 68: 62-66.
13. Singal R. An incarcerated appendix: Report of three cases and a review of the literature," *Hernia*. 2010; 16: 91-97.
14. Sharma H, Gupta A, Shekhawat NS. Amyand's hernia: a report of 18 consecutive patients over a 15-year period. *Hernia*, 2007; 11: 31-35.
15. Losanoff JE, Basson MD. Amyand hernia: A classification to improve management," *Hernia*. 2008; 12: 325-326.